

## Intraoral Chondroid Lipoma with Ossification – An Unusual Case

Dr. Madhuri Kate, Dr. Pruthviraj Jaybhaye, Dr. Nidhi Chaturvedi

Department of Pathology, ESI-PGIMS, Andheri, Mumbai-93

**Abstract:** Although adipocytic tumours are the most common mesenchymal tumours, chondroid variant is an extremely rare entity. Though proximal extremities, limb girdles and head, neck are common sites of occurrence, rarely cases of this unique entity have been reported in oral cavity. Chondroid lipoma due to its complex histology comprised of lipoblast like cells in myxoid and chondroid background, is aptly termed as pseudosarcomatous tumour. Importance of the knowledge of this distinct entity cannot be overestimated since it mimics soft tissue sarcoma. We report one such case of intra oral chondroid lipoma with ossification in young female. [ Kate M et al NJIRM 2012; 3(2) : 182-184]

**Key words:** Intraoral, Chondroid Lipoma, lipoblast like cells, ossification

**Author for correspondence:** Dr.Madhuri S. Kate, MD Pathology, Professor, Department of Pathology, ESI-PGIMS and Model Hospital, Andheri (East), Mumbai-93, e- mail : madhurikate65@gmail.com

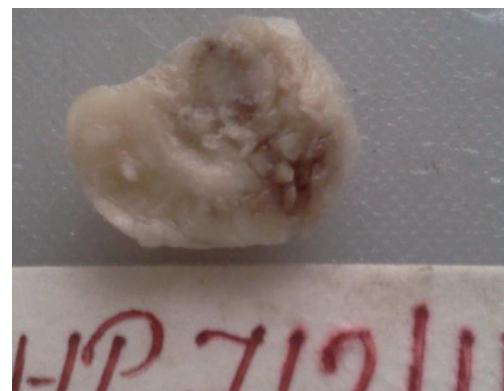**Introduction:** Adipocytic tumours represent the largest and single most common group of mesenchymal tumour encountered by the histopathologist.<sup>1</sup> They may occur anywhere in the body and consist of a large family of pathological subtypes, both benign and malignant.<sup>1</sup> The histopathology of these tumors may range from typical lipoma composed only of mature adipose tissue to variants of lipoma containing non-lipomatous elements such as spindle cell lipoma, chondroid lipomas, pleomorphic lipomas and many more.<sup>1</sup> Of these chondroid lipoma is an extremely rare variant of lipoma that may arise from the superficial muscular fascia, skeletal muscle or subcutis, usually in the region of the proximal extremities, or limb girdle and head and neck region.<sup>4,10</sup> Rare cases have been reported in the oral cavity.<sup>11</sup> Histologically the tumor is characterized by lipoblast like cells embedded within chondromyxoid background.<sup>2</sup> Due to its complex histopathological characteristics, and strikingly close resemblance to myxoid liposarcoma and extraskeletal myxoid chondrosarcoma, recognition of this benign tumor poses a great challenge to a histopathologist.<sup>1</sup> We report an unusual case of intraoral chondroid lipoma with areas of metaplastic bone formation, which to our knowledge has been only rarely described and thereby expand the spectrum of gross and microscopic pathological features that may occur with this tumor.

**Case Report:** A 22 year female from Mumbai, presented with slow growing painless palpable

lump within the oral cavity since 3 year duration. On clinical examination it was 2.5x2 cm mobile, non-tender soft to firm tissue mass arising from buccal mucosa. The mass was subcutaneous in location, well circumscribed and without any attachment to underlying bone. Mass was excised in toto under general anaesthesia.

**Gross Findings:** Grossly, the mass was well encapsulated and measured 2.2x2x1 cm (fig 1). Cut surface was yellowish grey in colour, predominantly greasy and soft with few chondroid like hard areas.

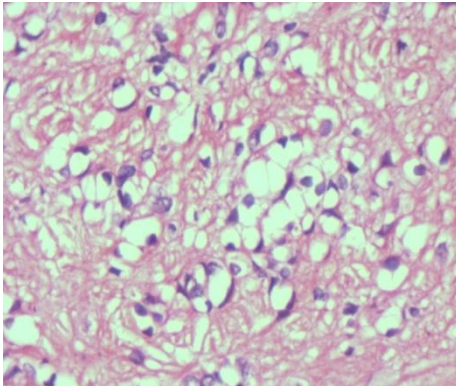
**Fig 1. Gross photograph of buccal mucosal soft tissue mass showing circumscribed yellowish grey tumour. Cut section shows predominantly soft firm areas with few chondro-myxoid areas**



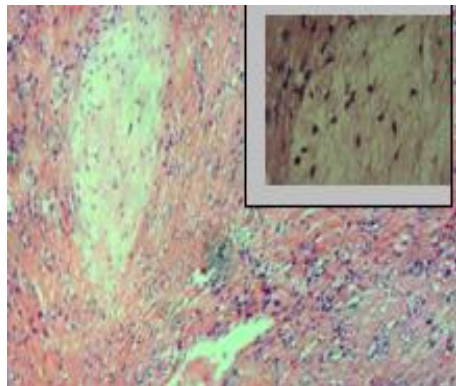
**Microscopy:** Multiple microscopic sections studied showed an encapsulated tumour composed of nests and cords of abundant uni- and multivacuolated lipoblasts like cells embedded in a prominent myxoid to hyalinized and fibroblastic matrix

admixed with a variable amount of mature adipose tissue. Some of the cells had vacuoles that indented the nucleus, indicative of lipoblastic differentiation (mimicking a lipoblast).

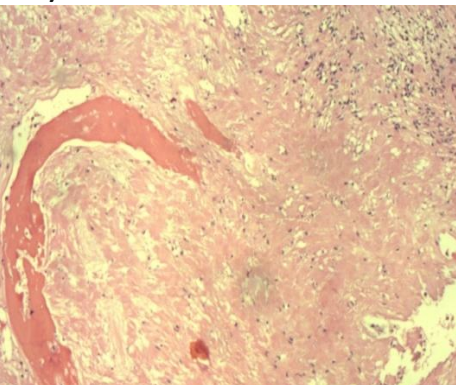
**Fig 2. Microscopy- Tumour lobules composed of uni and multivacuolated adipocytes with well defined cell borders within myxohyaline matrix imparting “chondroid” appearance (H&E, X 100).**



**Fig 3. Microscopy-Nests of small adipocytic cells with predominant area of myxoid change (H&E, X 40)**



**Fig.4 Microscopy showing areas of ossification (H&E, X 40)**



A scant amount of eosinophilic myxoid or hyalinized appearing matrix was present between the cells.

Many of the cells had well-defined cell borders. The matrix, vacuolated nature of the cytoplasm with a central nucleus and well-defined cell borders imparted a chondroid appearance to these areas. The findings were diagnostic of chondroid lipoma. In region of ossification, the bone was of cortical-type woven bone, which was being produced by osteoblastic cells.

**Discussion:** Meis and Enzinger described a peculiar lipomatous tumor in 20 patients, 16 females and 4 males, that had histologically chondroid-appearing areas they termed chondroid lipoma.<sup>4</sup> The tumors located in the extremities, trunk, head, and neck in decreasing frequency. Rare cases have been reported in the oral cavity.<sup>11</sup> The age of the patients ranged from 14 to 70 years, with a median of 36 years. There is predilection for adult women but can also occur in the paediatric age group.<sup>10</sup>

Clinically, the patient presents with a firm but mobile, slowly growing mass. Microscopically, the tumors were well demarcated. Some of the cases had thick fibrous capsules and were multinodular due to the presence of fibrous septae. The tumors were described as having areas in which the cells had vacuolated cytoplasm simulating hibernoma cells, lipoblasts, or chondroblasts admixed with a variable amount of myxoid matrix.<sup>5</sup>

Our case was a female of 22 years who presented with mass in the buccal mucosa and had diagnostic histopathological findings seen in chondroid lipoma, but was unusual in that there was bone formation within and at the periphery of the tumor. For a better understanding of the clinico-pathological correlation of this tumor, it is important to note that it is a tumor of adipocytes and does not have true cartilage differentiation and that the “chondroid” component is mixed with variable amounts of individual fat cells or lobules of mature adipose tissue in any given case. Specifically, in our case, the majority of the tumor was composed of sheets of the chondroid-appearing fat cells with a scant amount of eosinophilic myxoid to hyalinized matrix with fibroblastic proliferation. Lobules of mature adipose tissue as would be seen in conventional lipoma were admixed with the chondroid regions.

Although calcification and ossification are well-described secondary features of conventional lipoma, they have not been well-known or illustrated in cases of chondroid lipoma. In their original series of chondroid lipoma Meis and Enzinger state that calcification occurred in 10% of the cases.<sup>4</sup> Rarely, others have reported calcification or ossification in chondroid lipoma, but only described and illustrated the radiological features.<sup>8</sup>

The microscopic variants of lipoma have been described, like fibrolipoma, sclerotic lipoma, chondrolipoma, osteolipoma, myolipoma and angiomyxolipoma. Myxolipoma is a lipoma admixed with abundant mucoid substances and is considered to be a lipoma with a high degree of myxoid change, while chondroid lipoma shows nest-like or cord-like growth of lipoblasts. For this clinically benign neoplasm the main importance lies in its histological similarity with liposarcoma and chondrosarcoma, which have a poorer prognosis.<sup>12</sup> Extraskelatal chondrosarcoma does not contain adipocytes or lipoblast-like cells as a component of the tumour.<sup>5</sup> Myxoid liposarcoma can be distinguished from it by absence of plexiform vascular pattern and presence of chondroid-like but not myxoid matrix. A diagnosis of sarcoma entails consideration of radical surgery and post-operative radiotherapy while chondroid lipoma in contrast is cured by surgical resection.<sup>13</sup>

**Conclusion:** Chondroid lipoma is rare, benign, adipocytic tumour of diagnostic importance because of its complex pseudosarcomatous histology. Awareness of this benign tumour is essential in order to avoid serious erroneous diagnosis of soft tissue sarcoma.

#### References:

1. Weiss SW, Goldblum JR. Benign lipomatous tumors and liposarcoma. In: Weiss SW, Goldblum JR, editors. *Enzinger and Weiss's soft tissue tumors*. St. Louis: Mosby; 2001. p. 571–694.
2. Benjamin Hoch & George Hermann & Michael J. Klein & Ibrahim Fikry Abdelwahab *Skeletal Radiol* (2008) 37:475–480
3. Kim JY, Park JM, Lim GY, et al. Atypical benign lipomatous tumors in the soft tissue:

- radiographic and pathologic correlation. *J Comput Assist Tomogr* 2002; 26:1063–1068.
4. Meis JM, Enzinger FM. Chondroid lipoma. A unique tumor simulating liposarcoma and myxoid chondrosarcoma. *Am J Surg Pathol* 1993; 17: 1103–1112.
5. Nielsen GP, O'Connell JX, Dickerson GR, Rosenberg AE. Chondroid lipoma, a tumor of white fat cells. A brief report of two cases with ultrastructural analysis. *Am J Surg Pathol* 1995; 19: 1272–1276.
6. Lakshmiah SR, Scott KWM, Whear NM, Monogham A. Chondroid lipoma: a rare but diagnostically important lesion. *Int J Oral Maxillofac Surg* 2000; 29: 445–446.
7. Gomez-Ortega JM, Rodila IG, Basco Lopez de Lerma JM. Chondroid lipoma. A newly described lesion that may be mistaken for malignancy. *Oral Surg Oral Med Oral Pathol Oral Radiol Endod* 1996; 81:586–589. *Skeletal Radiol* (2008) 37:475–480
8. Green RAR, Cannon SR, Flanagan AM. Chondroid lipoma: correlation of imaging findings and histopathology of an unusual benign lesion. *Skeletal Radiol* 2004; 33: 670–673.
9. Sunitha Jacob, Debahuti Mohapatra. Chondroid lipoma: Apseudosarcomatous tumour of soft tissues. *Letters to editor, IJPM-52(2)*, April-June 2009
10. Kindblom LG, Meis-Kindblom JM. Chondroid lipoma: an ultrastructural and immunohistochemical analysis with further observations regarding its differentiation. *Hum Pathol*. 1998 Jan;29(1):98-100
11. Darling MR, Daley TD. Intraoral chondroid lipoma: A case report and immunohistochemical investigation. *Oral Surg Oral Med Oral Pathol Oral Radiol Endod* 2005;99: 331-33
12. Manna AK, Chattopadhyay A, Chowdhury K, Chowdhury MK, Dutta SK. Chondroid lipoma – A case report. *Indian J Pathol Microbiol* 2006; 49:422-424.
13. Con Vasili. Incidental finding of chondroid lipoma at total hip arthroplasty. *J South Orthop Assoc* 2000; 9:219-221.