

Histological Study of Adenomatous Goitre

Dr. Vipul P. Prajapati*, Dr. Jyoti C. Nayak**, Dr. Kinnar S. Desai***, Dr. H.R.Jadav****, Dr. H.R.Shah*****
Dr. C.A.Pensi*****

*Assistant Professor, ****Professor & Head - Dept of Anatomy, GMERS Medical College, Sola-Ahmedabad, **Assistant Professor,
Assistant Professor, **Associate Professor, *****Professor & Head - Dept of Anatomy, B.J. Medical College, Ahmedabad

Abstracts: Background & objectives: Multinodular goitre is probably the most common endocrine problem in the world today. Neither a well formulated nor a simple procedure is available for the management of MNG, hence the need for the present study. The aim was to study the various modes of presentation, the distribution with respect to age and sex and the usefulness of histological evaluation. Methods: This was a retrospective study of 100 cases of thyroid lesions during the period of April 2009 to October 2010. Results: Adenomatous goiter was found to be the commonest lesion with a frequency of 52 cases (52%). Most of the patients were female accounting for 90.39%. Most of the cases (53.85%) were noted in 21-40 years age group. Commonest presentation was swelling in front of the neck noted in 98% of cases. Conclusion: Commonest histological observation in the present study was adenomatous goitre in 52%. Majority of the patients were females with a M:F ratio of 1:9.4, with the commonest age group being 31-40 yrs. Almost all patients presented with swelling in front of the neck, with other complaints being that of pain, discomfort, dysphagia, dyspnoea and features of hyperthyroidism [Prajapati V et al NJIRM 2012; 3(2) : 65-68]

Key words: Adenomatous goiter, FNAC, Multinodular goiter, Thyroid

Author for correspondence: Dr. H.R.Jadav, Professor & Head, Anatomy Department, GMERS Medical college, Ahmedabad. Pin -300060, Email – drhrishihirishihirishi@gmail.com

Introduction: Thyroid enlargement is one of the most common disorders of the endocrine system. The reported incidence of both benign and malignant lesions in surgically treated thyroid swellings varies widely from one geographical area to the other¹. As Willis stated, for the thyroid gland, working in continuous state of interest having alternate periods of cellular activity and quittance in response to an array of exogenous and endogenous stimuli, it is not so surprising that it suffers from a wide variety of disease. A constant supply of thyroid hormones is necessary for growth, development and maintenance of metabolism and functional activity of most organs. Diseases of thyroid are manifested either qualitative and quantitative alterations in hormone secretion or enlargement of thyroid (goitre) or both.

Worldwide, nodular goitre remains a problem of enormous magnitude. It is estimated that no less than 5% of the world's population have goitres. Depending on the population studied, multinodular goitre (Image – I) occurs in upto 12% of adults. Nodular goiter can occur as a result of an endemic goiter due to iodine deficiency in the soil, water or food. Sporadic nodules may be caused by a variety

of conditions, most of them are benign in nature, but still can simulate malignancy clinically or radiologically. Nodular goiters are more common in women than in men and the nodularity increases with increasing age. The incidence of carcinoma in multinodular goitre has been reported as 5% to 10%².

Multinodular goitre (Image – I) is a common disease generally presenting with a lump in the neck alone or with "local" difficulty with breathing or dysphagia and/or change of voice. These symptoms appear to bear no relation to the weight of the gland or the age of the patient, although the weight of the gland does increase with age. Iodine uptake thyroid scan, Thyroid function test, ultrasonography of the gland and fine needle aspiration cytology (FNAC) can also play a significant role in establishing the preoperative diagnosis of malignancy, but FNAC is the modality of choice. Surgery has always played an important role in the treatment of thyroid disease, but not all patients with goitre require surgery. In MNG the principal indications for thyroidectomy are suspected malignancy in a dominant nodule, thyrotoxicosis, significant compressive symptoms, retrosternal extension and cosmetic deformity³. There should be no major medical contraindications to surgery. However, surgery is frequently recommended for young

women, patients with disease resistant to medical therapy and those with significant ophthalmopathy⁴. In this setting subtotal thyroidectomy has long been the standard operation, with the aim of restoring a euthyroid state.

The value of histological examination (Image – II) is well explained in patients with thyroid lesions where adjuvant treatment is dependent upon grade, severity and extent of invasion of disease. Many patients may be suspected of having a malignancy on pre-operative assessment in these cases histological examination may aid to rule out suspicion.

Material and Methods: Ethical committee permission was taken, before start of study. This is a retrospective study of 100 cases of thyroid gland lesions. The material for the present study comprised of specimens received at Central Laboratory, B.J.Medical College, Ahmedabad between April 2009 to October 2010 from patients admitted in Civil Hospital, Ahmedabad.

The resected specimens consisted of 44 subtotal thyroidectomy, 23 hemithyroidectomy, 18 lobectomy, 4 near total thyroidectomy, 5 total thyroidectomy, 2 lumpectomy and 4 cases from incisional biopsy. All the details of the cases consisting of age & sex, clinical history, relevant investigations, gross features (size, shape, consistency and external surface), microscopic features and final diagnosis were noted.

The specimens were fixed in 10% formalin for 24-48 hours. Tissues were taken from the pathological lesions and processed by standard technique in the Yorco Automatic Tissue Processor for 24 hours; and paraffin blocks were made. The blocks were cut to give 4-5 micron thick sections and stained with haematoxylin and eosin. The slides were made, labelled and mounted in DPX. All the slides were studied with 10X and 40X magnification of light microscope.

Result: We reviewed 100 thyroid lesions. Out of these 76 (76%) were non-neoplastic lesions and 24 (24%) were neoplastic. In non-neoplastic lesions, Adenomatous goiter was found to be the

commonest lesion with a frequency of 52 (52%) followed by Colloid goitre 14 (14%), thyroiditis 4 (4%), benign cyst 2 (2%). In a total of 24 neoplastic lesions, 13 (13%) were benign and 11 (11%) were found to be malignant. (Table-I)

Table-I Distribution of lesions of thyroid

Type of lesion	No. of Cases	Percentage
Adenomatous goitre	52	52%
Colloid goitre	14	14%
Thyrotoxicosis	4	4%
Thyroiditis	4	4%
Thyroglossal cyst	2	2%
Follicular adenoma	13	13%
Thyroid malignancy	11	11%
Total	100	100%

Lesions of thyroid gland were more common in females than in males. Out of the 52 cases of adenomatous goitre there were 5 males and 47 females with male:female ratio being 1:9.4.(Table-II)

Table-II Sex distribution of Adenomatous goitre

Sex	No. of Cases	Percentage	Male : Female
Male	5	9.61%	1 : 9.4
Female	47	90.39%	

Lesions of thyroid gland were found to occur in all age groups from 2nd to the 7th decades. Lesions of thyroid gland were most common in the 3rd and 4th decades. For the adenomatous goitre most of the cases (53.85%) were noted in 21-40 years age group. The youngest patient was of 16 years and the oldest patient was of 76 years. (Table-III)

Most of the patients were presented with swelling in front of the neck (98%). Other symptoms were pain and discomfort in 10 cases (19.23%), palpitation in 5 cases (9.61%), dysphagia in 9 cases (17.30%), dyspnoea in 2 cases (3.84%). Increased sweating, increased appetite and weight loss accounted for 1 case (1.92%). (Table-IV)

Table-III Age distribution of Adenomatous goitre

Age group in years	No. of Cases	Percentage
<20	1	1.92%
21-30	13	25%
31-40	15	28.85%
41-50	10	19.23%
51-60	8	15.38%
>60	5	9.62%
Total	52	100%

Table-IV Presentation of Adenomatous goitre

Symptoms	No.of Cases	Percentage
Swelling in front of neck	49	98%
Pain and discomfort	10	19.23%
Palpitation	5	9.61%
Dysphagia	9	17.30%
Dyspnoea	2	3.84%
Increased sweating	1	1.92%
Increased appetite	1	1.92%
Weight loss	1	1.92%

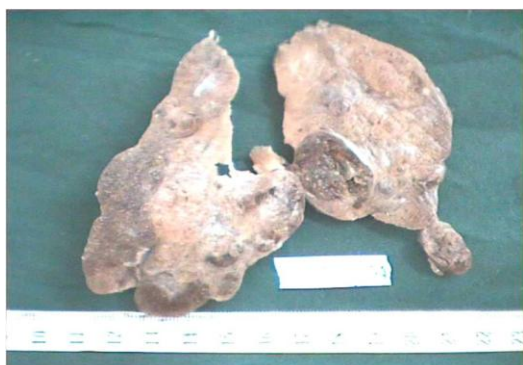

Image – I : Multinodular goitre (Gross appearance)

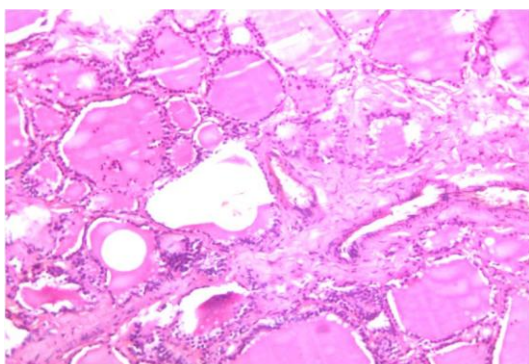


Image – II : Multinodular goitre (Microscopic appearance)

Discussion: The distribution of nodular goitre is worldwide. It has been estimated that at least 200 million people have goitre in the world⁵. It occurs in all races in all climates and at all inhabitable altitudes. In the present study, among all the lesions of thyroid adenomatous goitre (52%) was the commonest histological finding and that correlates with the study done by Salman Yousuf Guraya et al⁶(51.8%), Martin. A Nzegwu et al⁷ (44.2%) and Nazar Hussain et al⁸ (61.63%). The rest of the findings are also well comparable with the other studies. While in the study done by L. P. Bron et al⁹ adenomatous goitre was observed in 74.82%.

The MNG is common in 3rd - 4th decades, the reason being more TSH fluctuation noted during adolescence and in reproductive age group¹⁰. In the study conducted by Ahuja et al¹¹ and Kapoor M M et al¹² reported that majority of cases belong to the 3rd and 4th decades. The present study is comparable to the above studies.

Thyroid disorders are four times more common in women than in men and occur more often in people who live in geographic areas with iodine deficiency¹³. Nygaard B. et al¹⁴, Rehman A U et al¹⁵ and Antonio Alfonso et al¹⁶ reported male to female ratio of 1:8.8, 1:7.6 and 1:7 respectively. Ahuja¹¹ (3.5:1) and L.P. Bron et al⁹ (5.4:1) observed less number of female patients with adenomatous goitre. In all above studies, there was a female preponderance. The result of the present study (1:9.4) is comparable to the above studies.

The primary symptom of goitre is a swelling or lump on the front of the neck, which is due to an enlarged thyroid. In mild cases, this lump may not be problematic. In more serious cases, pressure from the goitre can interfere with swallowing, chewing or speaking. Other symptoms of goitre are related to dysfunction of the thyroid and hormone imbalance. In the present study, swelling in front of the neck was the most common presentation, like study carried out by Schlesinger¹⁷(97%). But pressure symptoms like dysphagia & dyspnoea were less observed in present study than the study done by Schlesinger¹⁷.

Conclusion: Commonest lesion in this study was adenomatous goitre. It accounted for 52% of all

thyroid lesions. Highest age incidence of adenomatous goitre was observed in the age group of 21-30 years (25%); youngest was of 19 years and oldest was of 75 years. Most of the cases of adenomatous goitre were females with a male: female ratio of 1:9.4. Swelling in front of the neck was the usual presentation in most of the cases.

References:

1. AL – Tameem MM. The Pattern of surgically treated thyroid disease in two general hospitals in Riyadh. *Saudi Med J* 1987; 8: 61–6.
2. Jameson JL, Weetman AP. Disease of the Thyroid Gland ch 320 in Harrison's Principles of Internal Medicine, vol 2, 16th ed, New York: Mc Graw Hill, 2005. Pp 2106-2117.
3. Mishra A, Agarwal A, Agarwal G, Mishra SK. Total thyroidectomy for benign thyroid disorders in an endemic region. *World J Surg* 2001; 25: 307–310.
4. Franklyn JA. The management of hyperthyroidism. *N Engl J Med* 1994; 330: 1731-1738.
5. John B. Hanks. Thyroid Chapter 32, Sabiston Textbook of Surgery, 16th edition. Townsend Jr. et al. Harcourt Asia Pvt. Ltd, India 2001, pp 603-628.
6. Salman Yousuf Guraya, Omer Al Faroug Eltinay: Total Thyroidectomy for Bilateral Benign Thyroid Disease: Safety Profile and Therapeutic Efficacy. *Kuwait Medical Journal* 2007; 39 (2): pages 149-152.
7. Martin. A Nzegwu et al: A Histological Update of Thyroid Lesions in Enugu, Nigeria: A 5- Year Retrospective Study. *Asian J. Exp. Biol. Sci.*, Vol 1 (2) 2010; pages 430 – 433.
8. Nazar Hussain et al: Pattern of surgically treated thyroid disease in Karachi: *Biomedica* Vol. 21, Jan. – Jun, 2005.
9. L. P. Bron and C. J. O'Brien: Total thyroidectomy for clinically benign disease of the thyroid gland. *British Journal of Surgery* 2004; 91: pages 569–574.
10. Das S. The thyroid and parathyroid in A concise textbook of surgery, 3rd ed, Calcutta, 2004, pp642-676.
11. Ahuja: Profile of nodular goitre. *J Assoc Phy Ind* 1968; 16: pages 699-707.
12. Kapoor M M: Solitary thyroid nodule. *Ind J Surg*, 1982; 12: pages 166-168.
13. Tan GH, Gharib H. Thyroid incidentalomas: management approaches to non palpable nodules discovered incidentally on thyroid imaging. *Ann Intern Med* 1997;126:226-31.
14. Nygaard B, Hegedus L, Gervil M, et al: "Radioiodine treatment of multinodular non-toxic goitre". *Br Med J* 1993; pages 828-832.
15. Rehman A.U et al: Histopathological Evaluation of 432 Cases of Goiter. *Annals* Vol No. 2 APR. – JUN; 2009.
16. Antonio, Alfonso, George S M, Chrisoudias M. Tracheal or oesophageal compression due to benign thyroid disorders. *Am J Surg* 1981; 142: pages 350- 354.
17. Schlesinger, M. J., Gargill, S. L. and Saxe, I. M. (1938). Studies in Nodular Goitre. *Journal of the American Medical Association*, 110, 1638.