

Study of Pterion And Incidence Of Epipteric Bones In Dry Human Skulls Of Gujarat

Dr. Chirag R. Khatri*, Dr. Sumit Gupta**, Dr. Jagdish S. Soni***

*Assistant Professor in Anatomy, GMERS Medical College, Gandhinagar, **Tutor, ***Associate Professor, Department of Anatomy, Medical College, Baroda, Gujarat-390020

Abstracts: Background: Pterion is present in floor of temporal fossa which is a meeting point of four bones, frontal and parietal bone superiorly and the greater wing of sphenoid and squamous temporal bone inferiorly. It is 'H-shaped' in most of the skulls. The most common variation is in its shape and presence of epipteric bone. Aim : To report the various types of pterion and incidence of epipteric bones in the human skulls and to compare with other racial groups from previous study. Methods: The present study was conducted using 311 dry, grossly normal human skulls from sources in Gujarat. Different types of pterion and the presence of epipteric bones were observed. Results: In the present study sphenoparietal variety of pterion was predominant and the incidence of epipteric bone was 11.73%. Conclusion: Knowledge of the presence of epipteric bones are important to prevent complications during burr hole surgery and to prevent misdiagnosis of fracture skull at the site of pterion. [Khatri C et al NJIRM 2012; 3(2) : 51-56]

Key Words: skull, pterion, epipteric bone, suture

Author for correspondence: Dr. Sumit Gupta, Department of Anatomy, 2nd floor, Medical College, near kothi Char rasta, Medical College, Baroda- 390001.e- mail: dr_sumitgupta@yahoo.co.in

Introduction: The floor of the temporal fossa is formed by the frontal and the parietal bones superiorly and the greater wing of sphenoid and squamous temporal bones inferiorly. All four bones of one side meet at an 'H' shaped junction termed the 'PTERION'¹. Pterion is the region mostly used as a guiding point where the position of deeper structures and their relations to the surface of the head are explained. This point is an important clinical landmark because the calvaria is thin in the region of pterion, which gets fractured easily at this point. It overlies anterior branch of the middle meningeal artery which is the most common artery to be damaged producing extradural haematoma, requiring burr hole surgery to evacuate haematoma². The Sylvian point, where the stem of lateral sulcus of cerebral hemisphere divides into its three limbs, anterior, ascending and posterior, coincides with pterion. Pterion also overlies Broca's motor speech area (area: 44, 45) and insula of cerebrum³. The pterion corresponds to the site of anterolateral fontanelle of neonatal skull which closes in the third month after birth.

SUTURAL BONES or Wormian bones are small irregular shaped bones, which are compensatory ossific inclusions occurring in the sutures and arising as separate ossifications between the main cranial elements. A sutural bone is occasionally present at the pterion. This bone is called pterion

ossicle or EPIPTERIC BONE or flower's bone. The presence of epipteric bone may lead to complications in making burr holes at the pterion and may be mistaken as fracture of the skull in case of trauma of the pterion region.

So the knowledge about the different types of pterion, exact location of centre of pterion and the incidence of the epipteric bones is important to prevent such complications.

Material and Methods: The present study was conducted using 311 dry, grossly normal adult human skulls from department of anatomy, Medical College, Baroda, B. J. Medical College, Ahmedabad, Pramukh Swami Medical College, Karamsad, M. P. Shah Medical College, Jamnagar, Government Medical College, Surat and SMIMER Medical College, Surat. Out of 311 skulls studied, skull cap of 22 skulls were not present but pterion site was intact.

Each skull was studied on both sides. Incidence of various types of pterion on both sides was observed. Incidence of epipteric bones in various types of pterion on right and left sides were calculated.

Result: Incidence of various types of pterion:

Three types of pterion were observed. (1) Sphenoparietal pterion (Figure: 1) where the greater wing of sphenoid bone articulates with the parietal bone in the form of letter 'H'. It was observed in 96.46% skulls in right side while 97.43% skulls shown it on left side. The overall incidence of sphenoparietal pterion was 96.9% shown in table no. 1 below.

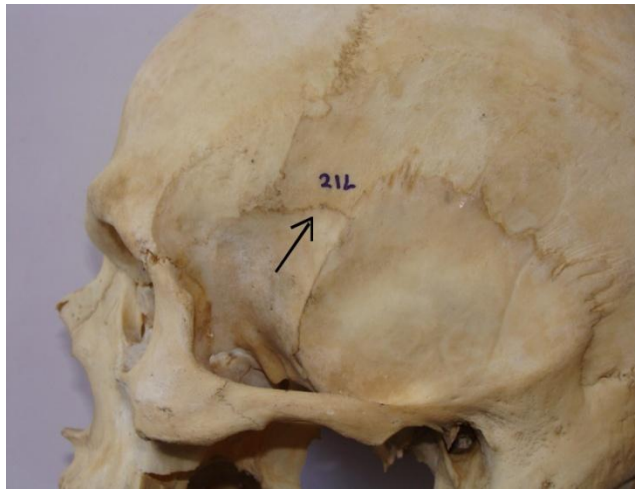


Figure 1: :Sphenoparietal type of pterion

(2) Frontotemporal pterion (Figure: 2) where the squamous part of temporal bone articulates with the frontal bone. It was observed in 3.21% skulls in right side while 2.57% skulls showed it on left side. The overall incidence of frontotemporal pterion was 2.9% as shown in table no. 1 below.

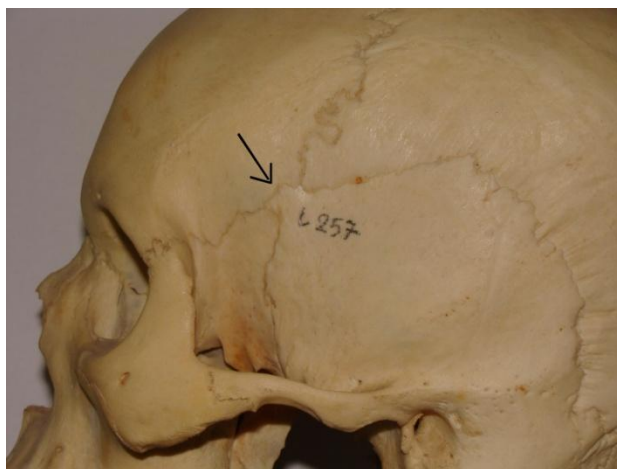


Figure: 2 Frontotemporal type of pterion

(3) Stellate pterion (Figure: 3) where all four bones articulate in the form of letter 'K' showing crossing of sutures. It was observed on right side in one

skull only. The incidence of this type of pterion was 0.2% shown in table no. 1 below.

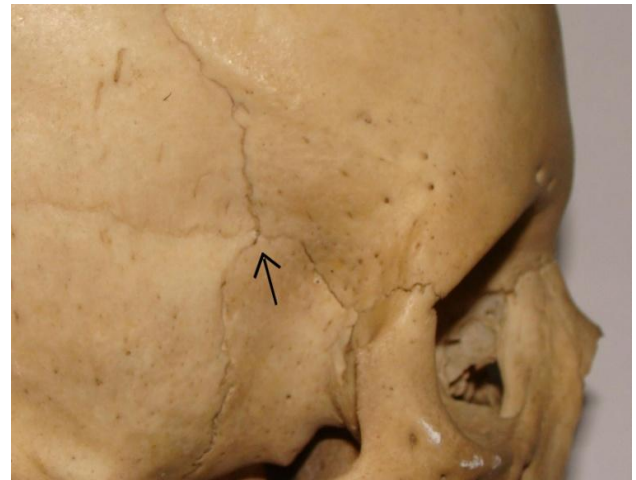


Figure:3 Stellate type of pterion

Table:1 Incidence of various types of pterion

Type of pterion	Side		Total (622 sides)
	Right(311 sides)	Left (311 sides)	
Sphenoparietal	300(96.46%)	303(97.4%)	603(96.9%)
Frontotemporal	10(3.21%)	8(2.57%)	18(2.9%)
Stellate	01(0.33%)	00(0.0%)	01(0.2%)

Incidence of epipteric bone: Epipteric bone (Figure:4) was observed in 73 pterion out of 622 sides. Epipteric bone was observed in 35 right sided pterion while 38 left sided pterion shown epipteric bone. So the incidence of epipteric bone was 11.25% on right side and 12.21% on left side. The overall incidence was 11.73% shown in table 2.

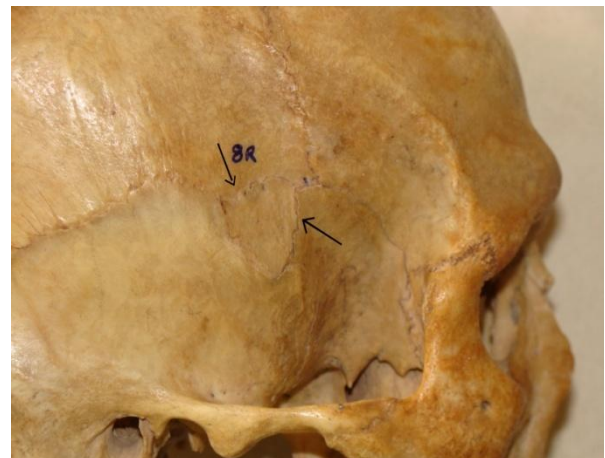


Figure 4: Epipteric bone in sphenoparietal pterion

Table: 2 Incidence of epipteric bone

Side	No of pterion observed	Pterion showing epipteric bone	% of pterion showing epipteric bone
Right	311	35	11.25%
Left	311	38	12.21%
Total	622	73	11.73%

Correlation of presence of epipteric bone with type of pterion: EpIPTeric bone was present in 12.54% left sided sphenoparietal pterion and in 11.66% right sided sphenoparietal pterion. EpIPTeric bone was observed in overall 12.10% sphenoparietal pterion as shown in table 3 below. No epIPTeric bone was observed in other two types frontotemporal and stellate pterion.

Table 3: incidence of epipteric bone in various types of pterion

Type of pterion	Side	No of pterion observed	No of pterion showing epipteric bone	% of pterion showing epipteric bone
Sphenoparietal	Right	300	35	11.66
	Left	303	38	12.54
	Total	603	73	12.10
Frontotemporal	Right	10	00	0.0
	Left	08	00	0.0
	Total	18	00	0.0
Stellate	Right	01	00	0.0
	Left	00	00	0.0
	Total	01	00	0.0

Discussion: In the present study three types of pterion were observed, i.e; sphenoparietal, frontotemporal and stellate. Present Study shows predominance of sphenoparietal type of pterion (96.9%) while incidence of frontotemporal type of pterion was 2.9% which was relatively lower than the other studies as shown in table 1. Bilodi AKS et al⁵ shows very higher incidence of frontotemporal type (22.05%).

Stellate type of pterion is rare in present study (0.2%) compared to other studies shown in table 4. Bilodi AKS et al⁵ shows very higher incidence of

stellate type of pterion(8.82%) compared to other studies as shown in table 4.

Table 4: Comparison of incidence of pterion between various studies:

	Type of pterion	Spheno parietal	Fronto Parietal	Satellate	
1	Present study	96.9%	2.9%	0.2%	
2	Saxena R.C. et al ⁴	84.72%	10.01%	5.17%	
3	Bilodi AKS et al ⁵	69.13%	22.05%	8.82%	
4	Ararwal A.K. et al ⁶	93.48%	4.35%	2.17%	
5	Manjunath K.Y. et al ⁷	93.55%	3.52%	2.93%	
6	Saxena S.K. et Al ⁸	Nigerians	84.73%	10.11%	5.06%
		Indians	95.30%	3.46%	1.38%
7	Oguz O. et al ⁹	88.46%	9.61%	1.92%	

Incidences of sphenoparietal type of pterion on right and left side in present study was 96.46% and 97.43% respectively as shown in table 1. It showed a very little difference. Manjunath K. Y. et al⁷ observed that sphenoparietal type of pterion was most common (93.55%) in south Indian skulls as shown in table 4.

Saxena S.K. et al⁸ also observed predominance of sphenoparietal type of pterion in Indian population (95.30%). While Oguz O. et al⁹ observed predominance of sphenoparietal type of pterion in Turkish population (88.46%) as shown in table 4.

Frontotemporal type of pterion was dominant in primates while sphenoparietal is the type dominant in homosapiens. The anterosuperior segment of the squamous part of temporal bone of lower primates got detached from its parents and got incorporated in the posterosuperior angle of the greater wing of sphenoid, thereby changing the pterion pattern from frontotemporal of primates to sphenoparietal type pterion of homosapiens.

Present study shows relatively higher incidence of epIPTeric bone (11.73%) compared to Ersoy M., Evliyaoğlu C., Bozkurt MC. Turquie et al¹⁰ (2003) (9%), Study in north Indian population; Gopinath K., Dhall U., Chhabra S. et al¹¹ (1998) (6.74%) and Nigerian skulls Saxena S.K. et al⁸ (3.79%) as shown

in table 5. Manjunath K. Y. et al⁷ observed that incidence of epipteric bone was 17.30% in south Indian skulls which is higher than the incidence of present study as shown in table 5. Epipteric bone was associated with the sphenoparietal type of pterion only in present study. Present study shows relatively higher incidence of epipteric bones 11.73%.

Table 5: Comparison of incidence of epipteric bone in various studies:

1	Present study		11.73%
2	Manjunath K.Y. et al ⁷		17.30%
3	Ersoy M., Evliyoaglu C., Bozkurt MC., Turquie et al ¹⁰		9.0%
4	Gopinath K., Dhall U., Chhabra S. et al ¹¹		6.74%
5	Saxena S.K. et Al ⁸	Nigerians	3.79%
		Indians	11.79%

Conclusion: Burr hole surgery is frequently performed at the site of pterion to evacuate extradural haematoma of anterior branch of middle meningeal artery. The presence of epipteric bones may lead to complications in making burr holes at the pterion. The sutural bone may be mistaken as fracture of skull in case of trauma of the pterion region. The fusion of epipteric bone with the temporal at times creates the deceptive appearance of a frontotemporal type of pterion. This study is useful for the Neurologists, Radiologists and Anthropologists.

References:

1. Standring Susan. Gray's anatomy, the anatomical basis of clinical practice 40th edi. Churchill Livingstone, Elsevier.2008; p. 403, 412, 418, 426,469, 529.
2. Snell Richard S. Clinical Anatomy by Regions, 8th edi. Lippincott. Williams and Wilkins,2008; p.673, 686
3. Moore Keith L. Clinically Oriented Anatomy, 2nd ediWilliams and Wilkins, London. 1985; p. 796, 798, 800, 862, 909, 980.
4. Saxena R. C. Study of Pterion in skulls of Awadh area in and around Lucknow, Kathmandu University Medical Journal,2003 Vol-1, p.32, 33
5. Bilodi AKS, Gupta SS. Pterion formation and its variation in Indo Nepalese skulls', Journal of

Nepalgunj Medical College, Vol-2,July 2002; p. 1-3

6. Agarwal A. K., Singh P. Pterion formation and its variations in the skulls of North India, Anthrop. Anz.1980; p. 38, 265-269
7. Manjunath K. Y., Thomas IM. Pterion variation and epipteric ossicles in south Indian Skulls, Journal of the Anatomical Society of India, Dec 1993, 42(2), p.85-94
8. Saxena SK, Jail SP. A comparative study of pterion formation and its variations in the skulls of Nigerians and Indians. Anthrop. Anz. 1988. Mar, 46(1), p.75-82
9. Oguz O, Sanli SG. The pterion in Turkish male skulls' Surg Radiol Anat. 2004. Jun, 26(3), p.220-24.
10. Ersoy M., Evliyoaglu C. Epipteric bones in the pterion may be surgical pitfall. Minimally Invasive Neurosurgery 2003; Vol-46, p. 363-365.
11. Gopinathan K., Dhall U., Chhabra S. Sutural bones in the North Indian population, J. Anat. Soc. India. 1998; 47(2), p.91-96