

Morphometric Study Of Pterion In Dry Skull Of Gujarat Region

Dr. Ankur Zalawadia*, Dr. Jignesh Vadgama**, Dr. Srushti Ruparelia*, Dr. Shailesh Patel***, Dr. S. P. Rathod****, Dr. S. V. Patel*****

*Assistant Professor, **Tutor, ****Professor and Head, Department of Anatomy, Medical College, Bhavnagar; ***Associate Professor, Department of Anatomy, GMERS, Medical College, Gotri; *****Dean, GMERS, Medical College, Gandhinagar.

Abstract: The pterion is a commonly used landmark on neurocranium; classified in four types: sphenoparietal, frontotemporal, stellate and epipterice. In this study we have found out morphology and location of pterion of skull of Gujarat region and comparison of their morphology with other populations. 42 skulls of unknown gender were examined on both sides from Department of Anatomy, Medical College Bhavnagar. Measurements of the location of the pterion were made by using stainless steel callipers. Sphenoparietal was the most common form comprising 91.7%. Measurements between from center of pterion to posterior end of frontozygomatic suture, vertical distance to upper margin of zygomatic arch, horizontal distance to lateral margin of optic canal and horizontal distance to outer end of the sphenoid ridge on the lesser wing of the sphenoid were taken. Anatomical variations of the pterion, which are of interest to anthropologists, forensic pathologists and surgeons, deserve further investigation in other populations from different areas.

Key words: Pterion, Morphometry, Skull

Corresponding Author: Dr. Ankur Zalawadia, B-101, Shikhar Apt. Opp. Home School, Takhteshwar, Bhavnagar-362001, Gujarat, E mail :grayngle@yahoo.com

INTRODUCTION: Pterion is defined as an H-shaped small circular area formed by the junction of four bones: frontal, parietal, temporal and sphenoid on norma lateralis of the skull^{1,2,3,4}, being approximately 4.0 cm above the zygomatic arch and 3.5 cm behind frontozygomatic arch^{2,4}. Pterion has a different morphology being a meeting point of skull base, calvarium and the skeleton part of facial anatomy⁵. It also forms the floor of temporal fossa^{2,4}.

This pterion junction has been used as a common extra-cranial landmark for surgeons in microsurgical and surgical approaches towards important pathologies of this region^{1,5,6,7,8}. However this point is an important landmark for anterior branch of middle meningeal artery, Broca's motor speech area to the left, insula, the lateral (Sylvian) cerebral fissure⁸, for the pathologies of optic nerve, orbit, sphenoidal ridge^{1,3,7,9} and for the anterior circulation aneurysm and tumours^{6,7}. The pterion is also commonly used in cranial structure closure methodology as an important guide for age

estimation and sex determination in archeologically and forensic specimens¹⁰. Four types of pterion were defined by Murphy¹¹ (Figure-1).

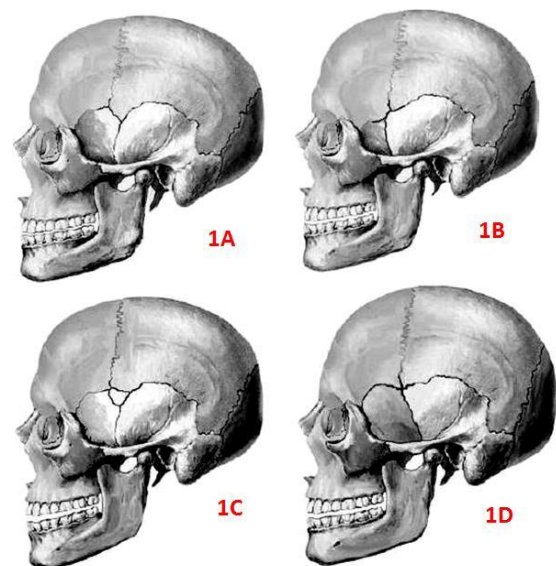


Figure-1 Types of the pterion. : 1A-Sphenoparietal; 1B-Frontotemporal; 1C-Epipterice; 1D-Stellate

The sphenoparietal type is defined as a sutural pattern in which the sphenoid and parietal bones are in direct contact. Conversely, the frontotemporal type is a sutural pattern in which the frontal and temporal bones are in direct contact. The stellate type is characterized by articulation of four bones (frontal, parietal, temporal and sphenoid) at a point.

The epipteretic type is defined by presence of a small sutural bone between the parietal bone and the greater wing of the sphenoid bone. Present study was conducted to determine and map the location of the pterion, and to define its type, in skulls of western India.

MATERIAL AND METHOD: Total 42 dry human adult aged skull of unknown sex without any gross pathology or abnormality were studied.

On both the left and right sides of each skull, the sutural pattern of the pterion was determined based on descriptions (sphenoparietal, frontotemporal, stellate and epipteretic types). A circle of smallest radius was drawn connecting the four bones involved in the formation of the pterion, the center of which was taken as the center of the pterion. Following measurements taken twice then averaged so as to minimize bias errors, using standard stainless steel callipers with an accuracy of 0.1 mm, of the distances between the pterion and specific identifiable bony landmarks (Figure-2,3):

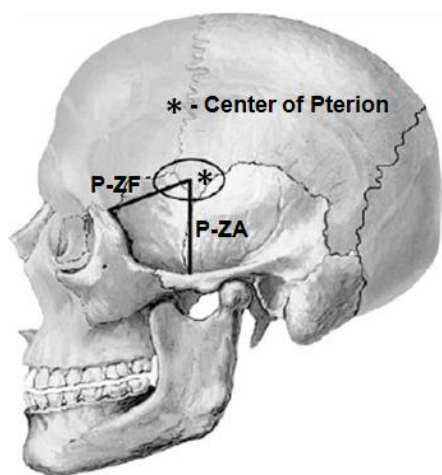


Figure-2 Distance measurements on lateral aspect of skull

- P-FZ: the distance from the center of the pterion to the posterolateral aspect of the frontozygomatic fissure,
- P-ZA: the vertical distance from the center of the pterion to the zygomatic arch,
- P-LWS: the horizontal distance from the internal aspect of the center of the pterion to the outer end of the sphenoid ridge on the lesser wing of the sphenoid,
- P-OC: the horizontal distance from the internal aspect of the center of the pterion to the lateral margin of the optic canal. The data obtained were analyzed using standard statistical software.

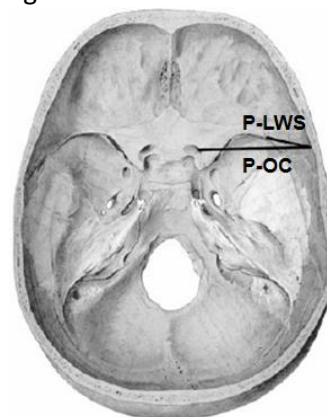


Figure-3 Distance measurements in interior of skull

RESULTS: All types of the pterion were found in skull of Gujarat region of western India (Table-1). The sphenoparietal pterion was the predominant type in both sides. A single stellate type was observed in left side of skull while on the opposite side there was sphenoparietal type; this was the only asymmetry of pterion seen.

Table-1 Frequency of pterion types observed on the right and left sides of the skull

Pterion type	Right side	Left side	Both side
	n=42	n=42	n=82
Sphenoparietal	92.9%	90.5%	91.7%
Frontotemporal	2.4%	2.4%	2.4%
Stellate	0	2.4%	1.2%
Epipteretic	4.8%	4.8%	4.8%

The means and associated standard deviations of the various linear measurements taken from the center of the pterion are shown in (Table 2). No obvious differences between the right and left sides were observed for any of the measurements ($p>0.05$).

Table-2 Mean and associated standard deviations of the linear distance (cm) from pterion to specific identifiable bony landmarks

Distance	Right side (n=42)	Left side (n=42)
	Mean±SD cm	Mean±SD cm
P-FZ	3.73±0.51	3.55±0.42
P-ZA	3.12±0.44	2.97±0.33
P-LWS	1.36±0.35	1.33±0.22
P-OC	4.52±0.32	4.37±0.23

DISCUSSION: Knowledge and understanding of the type and location of the pterion and its relation to surrounding bony landmarks is important, especially with respect to neurosurgery. Detailed information can only readily be obtained from an examination of dry skulls to determine more precise relationships between bony landmarks and the underlying soft tissues.

In the present study sphenoparietal, Frontotemporal, stellate and epipteric types of pterion were observed (Table-1). Sphenoparietal type of pterion is most common seen in Asiatic Indians (95.1%)¹², Northern Indians (87.72%)³, South Indians (93.55%)¹⁴ and Nigerians (87.79% and 82.1%)^{12,15} same as in this study (91.7%); while it was significantly lower in Korean (76.5%)¹⁶ and Kenyan (66%)¹⁷ populations as compared to this study (Table-3).

Table-3 Comparison of the percentage of pterion types in different populations

Study/Population n (skull), sex	Type of pterion			
	Sphenoparietal	Frontotemporal	Stellate	Epipteric
	%	%	%	%
Saxena et al. ¹² , 1988, Nigerian, n=40, unknown sex	87.79	10.11	5.06	3.79
Saxena et al. ¹² , 1988, Indian, n=72, unknown sex	95.3	3.46	1.38	11.79
Manjunath et al. ¹⁴ , 1993, South Indian, n=172, unknown sex	93.55	3.52	2.93	17.3
Asala et al. ¹⁵ , 1996, Nigerian, n=212, unknown sex	82.1	23.6	-	5.7
Lee et al. ¹⁶ , 2001, Korean, n=149, unknown sex	76.5	-	-	40.3
Saxena et al. ³ , 2003, North Indian, n=203, both sex	87.72	10.01	5.17	0
Oguz et al. ⁷ , 2004, Turkish, n=26, male	88	10	0	2
Mwachaka et al. ¹⁷ , Kenyan, n=50, both sex	66	15	7	12
Present study, 2009, Western Indian, n=42, both sex	91.7	2.4	1.2	4.8

The incidence of the frontotemporal type of pterion has also been observed to vary in different groups, being reported of 10.11–23.6% in Nigerians^{12,15}, 15% of Kenyans¹⁷, 41.1% of Papuan skulls¹⁸, which

are significantly higher than present study. In the present study the frequency of a frontotemporal type pterion was 2.4% being closest to that reported in other populations of India (Table-3)^{12,14}. According to previous studies, the sphenoparietal

type of pterion is the dominant form in humans whereas the frontotemporal type is dominant in nonhuman primates^{3,7,12,16,19,20}. In primate evolution, the anterosuperior segment of the squamous part of the temporal bone of lower primates became detached from its parent and incorporated into the posterosuperior angle of the greater wing of the sphenoid bone of humans, thereby changing the pterion pattern from the frontotemporal type of nonhuman primates to the sphenoparietal type of humans^{3,19}.

An epipteric type pterion was observed in a small number of skulls (4.8%) in the present study, being significantly less than that reported in Nigerians (23.6%)¹⁵, Australian Aborigines (18.5%)¹¹ and Northern Indians (10.01%)³ but similar to that in South Indians (3.52%)¹⁴.

The pterion has been reported to lie 4.0 cm above the zygomatic arch and 3.0–3.5 cm behind the frontozygomatic suture². In the present study the pterion was 3.73±0.51 cm and 3.55±0.42 cm behind the frontozygomatic suture, and 3.12±0.44 cm and 2.97±0.33 cm above the zygomatic arch on the right and left sides respectively (Table 2).

The lesser wing of the sphenoid is a common site for meningiomas. The pterional approach may be used to reach the tumor, particularly if it is located laterally, in which case the distance between the internal aspect of the pterion and the lateral end of the sphenoid ridge is an important measurement.

In the present study this distance was found to be 1.40±0.33 cm and 1.48±0.32 cm on the right and left sides respectively (Table 2). The pterional approach may also be used to access the optic canal, in which case the distance between the internal aspect of the pterion and the medial margin of the optic canal is an important measurement. This distance was found to be 4.39±0.40 cm and 4.36±0.40 cm on the right and left sides respectively (Table 2).

CONCLUSION: Knowledge of the location and relations of the pterion is important in relation to surgical intervention, particularly with respect to

the course of the branches of the middle meningeal artery and Broca's motor speech area on the left side. The distances between the pterion and the lesser wing of the sphenoid and optic canal are of practical importance in surgical approaches to these regions via the pterion.

ACKNOWLEDGEMENTS: We are thankful to, Dean, Govt. Medical College, Bhavnagar, Gujarat (India) for providing facility to conduct research project.

REFERENCES:

1. Ersoy M, Evliyaoglu C, Bozkurt MC, Konuksan B, Tekdemir I, Keskil IS. Epipteric bones in the pterion may be surgical pitfall. *Minim Invasive Neurosurg* 2003;46:364–365.
2. Moore KL, Dalley AF. *Clinically oriented anatomy*, 4th edn. Lippincott Williams & Wilkins, Baltimore, 1999;836–842.
3. Saxena RC, Bilodi AKS, Mane SS, Kumar A. Study of pterion in skulls of awadh area-in and around Lucknow. *Kathmandu Univ Med J* 2003;1:32–33.
4. Standing S, Ellis H, Healy JC, Johnson D. *Gray's anatomy*, 39th edn. Elsevier Churchill Livingstone, London, 2005;442–471.
5. Feng WF, Qi ST, Huang SP, Huang LJ. Surgical treatment of anterior circulation aneurysm via pterion keyhole approach. *Di Yi Jun Yi Da Xue Xue Bao* 2005;25,546-8.
6. Cheng WY, Lee HT, Sun MH, Shen CC. A pterion keyhole approach for the treatment of anterior circulation aneurysms. *Minim Invasive Neurosurg* 2006;9:257–262.
7. Oguz O, Sanli SG, Bozkir MG, Soames RW. The pterion in Turkish male skulls. *Surg Radiol Anat* 2004;26:220–4.
8. Urzi F, Iannello A, Torrisi A, Foti P, Mortellaro NF, Cavallaro M. Morphological variability of pterion in the human skull. *Ital J Anat Embryol* 2003;108:83–117.
9. Lang J. The pterion region and its clinically important distance to the optic nerve, dimensions and shape of the recess or the temporal pole. *Neurochirurgia (Stuttg)* 1984;27:31–35.
10. Lovejoy CO, Meindl RS, Mensforth RP, Barton TJ. Multifactorial determination of skeletal age at death: a method a blind tests of its accuracy. *Am J Phys Anthropol* 1985;68:1-14.

11. Murphy T. The pterion in the Australian aborigine. *Am J Phys Anthropol* 1956;14:225-44.
12. Saxena SK, Jain SP, Chowdhary DS. A comparative study of pterion formation and its variations in the skulls of Nigerians and Indians. *Anthropol Anz* 1988;46:75-82.
13. Wang Q, Opperman LA, Havil LM, Carlson DS, Dechow PC. Inheritance of sutural pattern at the pterion in Rhesus Monkey skulls. *Anat Rec Discov Mol Cell Evol Biol* 2006;288:1042-9.
14. Manjunath KY, Thomas IM. Pterion variants and epipteric ossicles in South Indian skulls. *J Anat Soc India* 1993;42:85-94.
15. Asala SA, Mbajjorgu FE. Epigenetic variation in the Nigerian skull: sutural pattern at the pterion. *East Afr Med J* 1996;73:484-6.
16. Lee UY, Park DK, Kwon SO, Paik DJ, Han SH. Morphological analysis of the pterion in Korean. *Korean J Phys Anthropol* 2001;14:281-9.
17. Mwachaka PM, Hassanali J, Odula P. Sutural morphology of the pterion and asterion among adult Kenyans. *Braz J Morphol Sci* 2009;26:4-7.
18. Williams LP, Bannister LH, Berry MM, Collins P, Dyson M, Dussek JE, Ferguson MWJ. Gray's anatomy, 38th Edn. Churchill Livingstone, London, 1998;568,595
19. Ashley-Montagu FM. The anthropological significance of the pterion in the Primates. *Am J Phys Anthropol* 1933;18:159-336.
20. Matsumara G, Kida K, Ichikawa R, Kodama G. Pterion and epipteric bones in Japanese adults and fetuses with special reference to their formation and variations. *Acta Anatomica Nipponica* 1991;66:462-71.