

Study of Nutrient Foramina of Adult Dry Femur

Ankur Zalawadia*, Shailesh Patel**

*Associate Professor, **Professor and Head, Department of Anatomy, Government Medical College, Bhavnagar, Gujarat

Abstract: Introduction: Femur is highly rich in blood supply by various surrounding arteries of lower limb. The arteries of shaft (diaphysis) are known as nutrient arteries. The purpose of this study was to find the number, site and direction of nutrient foramina over the shaft of the femur which will be helpful the surgeons for treatment planning. Methodology: Unpaired 102 dry femurs, 50 of female (27 right and 23 left) and 52 of male (27 right and 25 left) devoid of any gross pathology were used to find the number and site of nutrient foramina of femur from Department of Anatomy, Govt. Medical College, Bhavnagar in year 2005. They were examined by magnifying glass and hypodermic deedless. The data were statistically analyzed. Result: 1. Number of foramina: Out 102 bones - 2 bones have no foramina, 44 have 1 foramina, 41 have 2 foraminas, 10 have 3 foramina, 3 have 4 foramina, 1 has 5 and 1 has 6 foramina. 2. Site: 80.95% of foramina are in the middle 1/3 of the shaft. No nutrient foramina found in upper and lower 1/6 of the femur. The mean of femoral foraminal index is 49.88. 3. All foramina were directed upwards towards the upper end of femur. Conclusion: The data received in this study were analyzed and compared with previous studies. The findings in this study will be helpful during various surgeries over femur like fracture treatment, bone grafting and vascular surgeries of lower limb. [Ankur Z NJIRM 2017; 8(4):38-40]

Key words: Nutrient foramina, bone, femur

Author for correspondence: Ankur Zalawadia, Associate Professor, Department Of Anatomy, Govt. Medical College, Bhavnagar, Gujarat. E-Mail: grayngle@yahoo.com M: 09426539848

Introduction: Nutrient artery is a main source of a blood to a long bone and is very important during its active growth¹ and the early stages of ossification². It is very important that the nutrient blood supply is preserved in free visualization bone grafts so that the Osteocytes and Osteoblasts in the bone graft survive and the healing of the graft to recipient bone is facilitated with the usual replacement of the graft by creeping substitution³. Knowledge of the localization of nutrient foramina can be useful in certain surgical procedures to preserve the circulation^{4,5,6,7}. In this study the site, number and direction of the nutrient foramina of femur have been studied and relevant literature reviewed and compared.

Methods: Unpaired 102 dry femurs, 50 of female (27 right and 23 left) and 52 of male (27 right and 25 left) devoid of any gross pathology were studied at Dept. of Anatomy, Govt. Medical College, Bhavnagar in year 2005. All the foramina observed by magnifying glass and inserted the 22 & 24 gauge needles on the different surface and borders of the femur and were noted. It is considered that foramina within 1 mm from any border were taken to be lying on that border of the bone. In order to describe the localization of the foramina the femur was divided into six equal parts over its length. The foraminal index for femur was calculated by using the formula $I = (DNF/TL) \times 100$ where I = foraminal index, DNF = the distance from proximal end of femur to nutrient foramen, TL = total length of femur⁸.

Table-1 Number of nutrient foramina and their distribution on femur

No. of foramina	No. of femur		Total	%	Linea aspera	Medial lip	Lateral lip	Anterior surface	Medial surface	Lateral surface	Popliteal surface
	Right	Left									
0	1	1	2	1.9	0	0	0	0	0	0	0
1	21	20	44	40.1	20	9	2	0	7	3	0
2	24	20	41	43.1	24	31	9	2	22	3	0
3	6	4	10	9.8	8	11	2	1	7	0	3
4	1	2	3	2.9	4	0	1	1	7	1	1
5	0	1	1	0.9	1	0	1	0	2	1	1
6	1	0	1	0.9	0	1	0	1	1	0	1
	54	48	102	100%	57	52	15	5	46	8	6

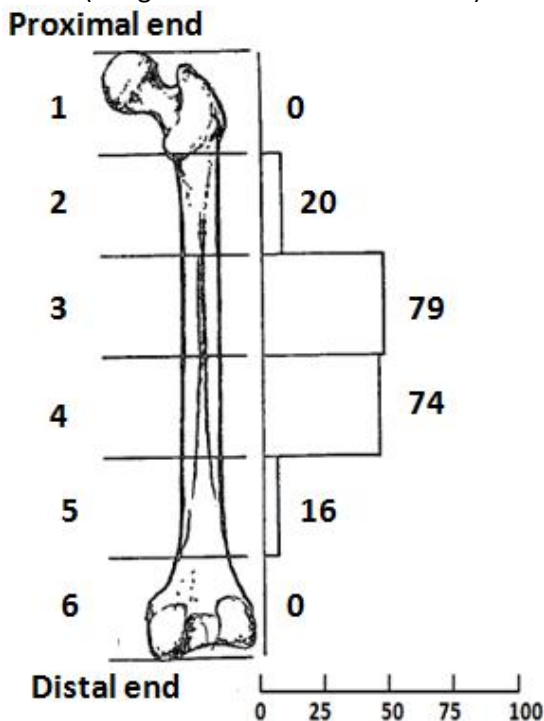
Table-2 The number and location of nutrient foramina and their foraminal index in the femur

Anatomical site	No. of foramina	Range	Mean	SD
Linea aspera (LA)	57	31.17-60.10	41.21	6.66
Medial lip (ML)	52	24.62-63.45	47.20	12.32
Lateral lip (LL)	15	27.42-64.34	41.44	11.19
Anterior surface (AS)	5	71.88-82.90	75.54	5.16
Medial surface (MS)	46	27.95-83.12	53.45	12.96
Lateral surface (LS)	8	43.30-75.44	54.45	12.23
Popliteal surface (PS)	6	64.45-73.34	71.03	4.21

The mean length of femur was 42.9 cm. Out of 102 femora 2 bones have no foramina, 44 have 1 foramina, 41 have 2 foramina, 10 have 3 foramina, 3 have 4 foramina, 1 has 5 and 1 has 6 foramina [Table 1]. Out of total foramina 124 foramina were on linea aspera and its medial and lateral lips [Table 1, 2]. The distribution of the foramina on femur was mostly in the 3/6th and 4/6th segments [Figure 1]. The mean foraminal index for the femur was found to be 49.88.

Fig:1 The distribution of the nutrient foramina with the foraminal index [FI]

(Image Reference – Piterest.com)



Mean of Femoral index = 49.88

Discussion: In this study the two foramina femur was the commonest (43.1%). This has been found in other studies, and reported as 50% by Mysorekar⁶, 60% by Forriol⁹, 46% by Sendemir¹⁰ and 55.6% by Laing¹¹. The nutrient foramen was absent in 1.9% of the bones,

being 3.33% in Mysorekar's study⁶. Other researchers have reported that there was at least one foramen in femur^{9, 10, 11}. While Laing¹¹ observed only two, Mysorekar⁶ three foramina, Sendemir¹⁰ noted 4, 5, 6, 7, 8, and 9 foramina. In this study maximum number of nutrient foramina noted was 6. In this study 66.66% of foramina were found on linea aspera and its medial and lateral lips, most often in the 3/6th and 4/6th of the bone. These results are accordance with the results obtained by other workers^{6, 9, 10, 11}.

Conclusion: the femur is highly vascular long bone of the body and supplied by perforating artery of profunda femoris artery. The study provides the information regarding site and number of nutrient foramina over the surface of femur.

The study confirms the previous studies for number and location of nutrient foramina of femur. The variation of nutrient foramina will be helpful during various surgeries over femur like fracture treatment, bone grafting and vascular surgeries of lower limb.

References:

1. Patake SM, Mysorekar VR. Diaphysial nutrient foramina in human metacarpals and metatarsal. *J Anat.* 1977;124: 299-304.
2. Lewis OJ. The blood supply of developing long bones with special reference to metaphysis. *J Bone Joint Surgery.* 1956;38:928-933.
3. Green DP. *Operative hand surgery*, 2nd edition, Churchill Livingstone, new York, Edinbrough, London. 1988;p-1248.
4. Fen G. Fibular blood supply. *Chin Med J.* 1981;94:396-400.
5. McKee NH, Haw P, Vettese T. Anatomic study of nutrient foramen in the shaft of the fibula. *Clinical Orthopedics Rel Res.* 1984;184:141-144.
6. Mysorekar VR. Diaphysial nutrient foramina in human long bones. *J Anat.* 1967;101:813-822

7. Tylor GI. Fibular transplantatio,-Microsurgical composite tissue transplantation. Mosby St Louis. 1979;pp418-423.
8. Hughes H. The factors determining the direction of the canal for the nutrient artery in the long bones of mammals and birds. Act Anat. 1952;15:261-280.
9. Forriol Campos F, Gomez L, Gianonatti M, Fernandez R. A study of the nutrient foramina in human long bones. Surg Radil Anat. 1987;9: 251-255.
10. Sendemir E, Cimen A. Nutrient foramina in the shaft of lower limb long bones: situation and number. Sirg Radiol Anat. 1991;13:105-108.
11. Laing PG, Kent P. The blood supply of the femoral shaft. J Bone Joint Surg. 1953;35:462-466.

Conflict of interest: None
Funding: None
Cite this Article as: Ankur Z, Shailesh P. Study of Nutrient Foramina of Adult Dry Femur. Natl J Integr Res Med 2017; 8(4):38-40