

CASE REPORT

A case of Cavernous Haemangioma over Urogenital site

Dr. Sudhir B Chandana*, Dr. Urvish R Parikh**, Dr. Vinay M Rohra***, Dr. Ankit B Kothari****, Dr. Simran R Bhalla*****

*Professor and Head, **Assistant Professor, ***Third Yr M.S. General Surgery, ****Second Yr M.S. General Surgery, Department of Paediatric Surgery, Sheth V.S.General Hospital, Ellisbridge, Ahmedabad

KEYWORDS : Haemangioma Vascular Abndrmalities Vulva

ABSTRACT

Hemangiomas are developmental vascular abnormalities and more than 50% of these lesions occur in the head and neck region, with the lips, tongue, buccal mucosa, and palate most commonly involved. One of the most complicated areas a hemangioma can develop in is the urogenital area or anogenital area. Most congenital hemangioma regresses spontaneously without treatment. However surgery is the therapy of choice in the isolated vascular lesions

INTRODUCTION

Hemangiomas are considered as benign tumors, being characterized by 3 stages: Endothelial cell proliferation, rapid growth and at last spontaneous involution. The pathophysiology of hemangiomas is attributed to genetic and cellular factors, mainly to monocytes, which are considered the potential ancestors of hemangioma endothelial cells. Imbalance in the angiogenesis, which causes an uncontrolled proliferation of vascular elements, associated with substances such as vascular endothelial growth factor (VEGF), basic fibroblast growth factor (BFGF) and indole-amine 2,3-dioxygenase (IDO), which are found in large amount during proliferative stages, are believed to be the cause.[1]

CASE REPORT

A full term, 37 week gestational age newborn, female, 1 day old, 2,540 g birth weight, born by normal delivery was transferred to our department for management of vulvovaginal mass since birth.

Physical examination revealed a 2x3x3 cm irregular shaped single friable mobile polypoid non pulsatile mass at the vulvovaginal junction with a connecting stalk at its superior pole with the inferior border of umbilical ring. There was no discharge from the mass but bled on touch. On auscultation no murmur or thrill was heard. The urethral and the vaginal openings were separate and did not reveal any communication with the mass on P/V examination. The labia majora and minora were well defined and separate from the swelling. The umbilical cord was normal in appearance with no discharge. No other congenital defects were noted or malformation found and 2D echo was normal.

Doppler USG was performed which showed a large vessel and vein coursing through the mass and suggested possibility of arteriovenous malformation. Blood tests and coagulation profiles were normal except mild physiological jaundice. There was no evidence of pathological jaundice due to increased hemolysis. There was no evidence of cardiomegaly or hyper dynamic circulation.

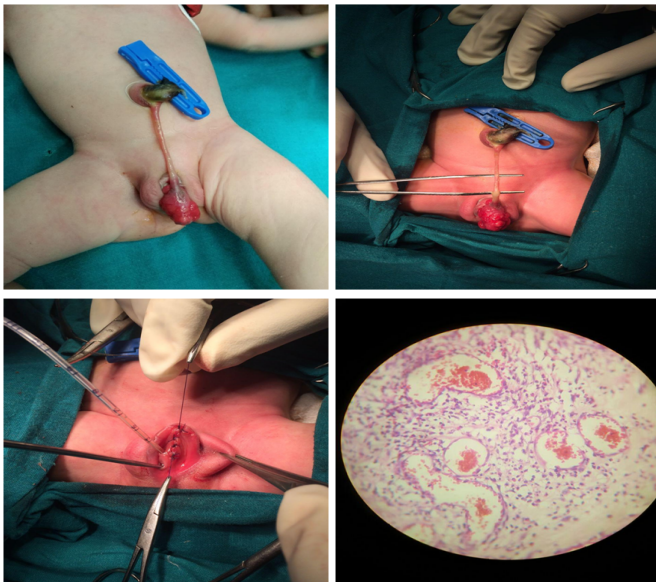
An excision and biopsy of the mass was planned on the 5th day of birth with appropriate pre-operative investigations and facility for blood transfusion available. The stalk was ligated and cut from the umbilical ring and the mass excised at base using cauterization. Reconstruction of labia minora done. Post-operative course was uneventful and the neonate was discharged home on post-operative day 4 (9th day of birth) being completely asymptomatic. The biopsy of the mass confirmed our findings as cavernous hemangioma.

DISCUSSION

Hemangiomas are developmental vascular abnormalities characterized by a proliferative growth phase and by very slow inevitable regression (involution phase). Risk factors include prematurity, low birth weight, female sex, and white race. Clinically hemangiomas are characterized as a soft, smooth or lobulated, sessile or pedunculated and may be seen in any size from a few milli-meters to several centi-meters. The color of the lesion ranges from pink to red purple and tumor blanches on the application of pressure, and hemorrhage may occur either spontaneously or after minor trauma.[2]. They are generally painless. Radiographic imaging is indicated preoperatively in selected cases where large

Correspondence Address : Dr Urvish R. Parikh

A-13, Amarkunj Society, Opp. CMC faston, Odhav Road, Ahmedabad-382415.
E-mail : urvishparikh1982@gmail.com



lesions may impinge on vital anatomical structures, such as the facial nerve or orbit. Computed tomography (CT) and magnetic resonance imaging (MRI) can also be used for volumetric analysis of hemangiomas and vascular malformations. Imaging resources can also be useful in both diagnostic differentiation and analysis of lesion features with regard to its size, extension and location, as well as for follow up of lesions treated under a systemic therapy.[3]

There are many treatment modalities reported in the literature including wait and watch policy[4][5] for

spontaneous involution, intralesional and systemic corticosteroid treatment, embolization, excision, electrolysis and thermo cautery, immunomodulatory therapy with interferon alfa-2a, and laser photocoagulation. Recent interest has centered on interstitial delivery of laser energy to photocoagulate vascular lesions. Currently, sclerotherapy is employed largely because of its efficiency and ability to conserve the surrounding tissues.

REFERENCES

1. Avilia ED, Molon RS, Conte Neto N, Gabrielle MA, hochuliVieriea E; Lip Cavernous Hemangioma in a Young child; Brazilian Dental Journal 2010 21(4):370-4
2. Klegman, Stanton, StGeme, Schor; Nelson Textbook of Paediatrics; 19th Edition; Chapter 650; Vascular Tumours; 3124; 1-5
3. Saiffudin T. Mama, Uzma Chaudhary; Journal of Paediatric and adolescent Gynaecology 2013; Vol 26(2); Pg60
4. Robert J. Kurman, Blaustein's Pathology of female genital tract, 2013; Vol(3); pg71-10
5. Fern A. Werth, Mark H. Lowitt; Journal of American Family Physician 1998 Feb 15; 57(4):765-773.